



Harrizul Rivai *et al*, Int. Journal of Pharmaceutical Sciences and Medicine (IJPSM),
Vol.3 Issue. 8, August- 2018, pg. 1-12

ISSN: 2519-9889
Impact Factor: 3.426

Propolis Hepatoprotector Effect on Liver Damage of White Mice Induced by Valproic Acid

Almahdy¹, Nur Azlin¹, Helmi Arifin¹, Harrizul Rivai^{1*}

¹Faculty of Pharmacy, Andalas University, Limau Manih Campus, Padang 25168, Indonesia
*E-mail address: harrizul@yahoo.co.id and harrizul@phar.unand.ac.id

Abstract

Propolis is a natural product that has a high antioxidant, namely Caffeic Acid Phenyl Ester (CAPE). CAPE has antioxidant activity 4-6 times stronger against oxidants, hydrogen peroxide, and free radicals, compared to vitamin C and N-acetyl-cysteine. Antioxidants are known to be hepatoprotective. This study aims to determine the effect of propolis on the activity of Serum Glutamic Pyruvic Transaminase (SGPT) and histological features of valproic acid-induced mouse liver. The experimental animals used were 24 mice divided into 4 groups randomly; group 1 was given distilled water, group 2 was given valproic acid dose 350 mg/kg body weight as an induction of liver damage, group 3 was given propolis dose 280 mg/kg body weight, and group 4 was given a dose of 560 mg/kg BB. Valproic acid-induced mice showed liver damage characterized by an increase in the average activity of SGPT, liver cell degeneration scores, and inflammatory cell (inflammation) scores. Provision of propolis dose 280 mg/kg body weight and 560 mg/kg body weight can reduce the average activity of SGPT, liver cell degeneration score and inflammatory score in liver cells. These results indicate that propolis with a dose of 280 mg/kg body weight and 560 mg/kg body weight gives a hepatoprotective effect. Propolis dose 280 mg/kg body weight is the best dose and is more effectively used as a hepatoprotective agent.

Keywords: Propolis, hepatoprotective agent, valproic acid, liver cell degeneration.

1. Introduction

The liver is a central organ in the body's metabolism (Sacher *et al.*, 1991). This organ has a complex function including having a role in the metabolism of carbohydrates, proteins, fats, vitamins, and drugs (Ganong, 2008). As a metabolic center in the body, the liver is susceptible to exposure to chemicals that are toxic so that it can cause damage such as inflammation of liver cells (hepatitis), cell degeneration and even cell death (necrosis) (Crawford, 2007).

Liver dysfunction is a significant problem in both developed and developing countries, especially in Indonesia (Ministry of Health, 2007). According to data from the Indonesian Heart Research Association in 2013, as many as 20-40% of liver diseases are caused by drugs and 50% of patients with acute hepatitis are the result of drug reactions to the liver. In the United States, there are about 2000 cases of acute liver failure that occur every year and more than 50% are caused by drugs (Mehta, 2016). A study in France showed about 13.9 cases / 100,000 population incidence of DILI (Drug-Induced Liver Injury) (Mehta, 2016). As many as 14% of DILI cases cause liver transplantation and even death in Singapore (Wai, 2006). Drug-Induced Liver Injury (DILI) is another term for drug-induced hepatotoxins (Cintha *et al.*, 2012).



Drugs that are said to be hepatotoxic are drugs that can induce liver damage (Sonderup, 2006). Liver damage inducing drugs are increasingly recognized as the cause of acute and chronic liver disease (Isabel Lucena *et al.*, 2008). Acetaminophen, a drug of Human Immunodeficiency Virus (HIV), troglitazone, anticonvulsants (such as valproic acid), analgesics, antibiotics, and anti-cancer drugs are common causative agents of DILI with death (Tajiri & Shimidzu, 2008). Valproic acid is one of the drugs that are hepatotoxic. Usually, valproic acid is used to treat epilepsy. In animal experiments, valproic acid has caused hepatocyte cells to degenerative and necrosis with the mechanism of enzyme induction and free radicals, resulting in oxidative stress which is characterized by increased lipid peroxidase and decreased levels of liver glutathione (Perucca, 2002).

Bhadauria *et al.*, (2007) suggested that propolis has the potential as a hepatoprotective agent in chronic liver injury by maintaining antioxidant activity. Propolis (bee glue), a natural product produced by honey bees (*Apis mellifera* L.) which has been used for thousands of years for traditional medicine (Viuda-Martos *et al.*, 2008). This product has attracted researchers in the last few decades because of its biological and pharmacological properties, such as antioxidants (Fabris *et al.*, 2013), anti-inflammatory (Funakoshi-Tago *et al.*, 2015), immunomodulators (Bufalo & Sforcin, 2015), anti-virus (Dota *et al.*, 2011), anti-bacterial (Seidel *et al.*, 2008), anti-cancer (Sawicka *et al.*, 2012) and hepatoprotective agent (Bankova, 2005). Propolis contains ferulic acid, caffeic acid and its esters namely caffeic acid phenethyl ester (CAPE) which functions as a hepatoprotective agent (Bankova, 2005). Hepatoprotector is a compound or substance that is effective in protecting liver cells from the effects of toxic substances that can damage the liver.

Some results of previous studies, showed that propolis can prevent liver cell damage of mice induced by paracetamol and increase in propolis dose can increase the protective power of liver cell damage of mice induced by paracetamol by giving propolis dose of 0.0104 mL/20 g of body weight and 0.0208 mL/20 g of weight body (Wulan, 2011). Then there has also been a study of the protective effect of propolis on liver damage done in mice with propolis doses of 25, 50, and 100 mg/kg of body weight on an oral basis, can protect the liver from damage induced by carbon tetrachloride (Veronica, 2016). Krisnansari *et al.* (2014), also proved that 0.054 grams of propolis and 0.108 grams per kg of body weight could improve liver function and fat in rats. Provision of 200 mg/kg of body weight propolis also provides a protective effect, can increase HDL and reduce LDL in mice. Plasma cholesterol levels that decrease or within reasonable limits will help the liver in carrying out its metabolic functions, and the occurrence of fatty liver can be prevented (Kolankaya *et al.*, 2002).

Propolis can capture hydroxy radicals, and superoxide then neutralize free radicals to protect cells and maintain the integrity of cell and tissue structures and can protect membrane lipids against unwanted reactions (Bendich, 1993). CAPE has antioxidant activity 4-6 times stronger against oxidants and hydrogen peroxide and free radicals, compared to vitamin C and N-acetyl-cysteine (NAC) (Nakajima, 2009). CAPE is the active side of flavonoids that works to maximize scavenger activity against free radicals, by reducing the activity of free radicals so that they are not too reactive (Cadenas & Packer, 2002).

This study generally aims to see the effect of propolis on liver damage to mice whether it can provide a protective effect on the liver damage of mice induced by valproic acid, and compare the increase in the dose of propolis with its protective effect. The specific purpose is to see the effect of propolis on SGPT activity, liver cell degeneration score and inflammatory (inflammation) cell score on liver induced by valproic acid. The parameters used are the levels of SGPT enzymes and liver histology.

2. Materials and methods

2.1 Tool and chemicals

The tools used were experimental animal pens, animal scales, analytic scales, microtube, micropipettes, centrifuges, vortices, spectrophotometer microplates, test tubes, stopwatches, oral sonde, glass objects, cotton, tweezers, surgical scissors and light microscopes. The experimental animals used are healthy female, white mice aged 2-3 months (body weight 20-30 grams) of 25 heads, The chemicals used are propolis, valproic acid, SGPT reagent kit (DSI®), distilled water, 96 % alcohol, xylol, liquid paraffin, glycerin, albumin, physiological NaCl, Bouin fixative solution, hematoxylin-eosin dyestuff.



2.2 Research design

In this study, experimental animals were divided into four groups, each group named Group 1, Group 2, Group 3 and Group 4.

Group 1: given distilled water 0.2 mL/20 g weight bed mice for 28 days.

Group 2: given distilled water 0.2 mL/20 g body weight of mice for 14 days, on day 15-28 given valproic acid 350 mg/kg body weight

Group 3: given propolis dose 280 mg/kg body weight of mice for 28 days, on day 15-28 given valproic acid 350 mg/kg body weight. Valproic acid is given 1 hour after propolis administration

Group 4: given propolis dose of 560 mg/kg body weight of mice for 28 days, on day 15-28 given valproic acid 350 mg/kg body weight. Valproic acid is given 1 hour after propolis administration.

2.3 Sample preparation

The propolis used is bee glue from PT X. This preparation contains 900 mg of pure propolis every one mL. This preparation is used in research without experiencing any treatment.

2.4 Preparation of experimental animals

In this study, the experimental animals used were female, white mice aged 2-3 months (body weight 20-30 grams) which were then divided randomly into four groups. Each group numbered six mice. Experimental animals before use are acclimated first for seven days. The animal fasted for 18 hours (drinking was still given) before the experiment. Animals are declared healthy and can be used if the difference in weight before and after acclimatization is not more than 10% and visually shows normal behavior (Ministry of Health, 1979).

2.5 Determination of propolis dose

In this study, the planned dose of propolis was 280 mg/kg body weight and 560 mg/kg body weight. The choice of the dose is based on previous research (Kolankaya *et al.*, 2002)

2.6 Determination of the dose of valproic acid

In this study, the dose of valproic acid used was 350 mg/kg BW of mice given orally for 14 days.

2.7 Blood collection of experimental animals

Animals are sacrificed by cutting blood vessels in the neck. Blood is collected as much as two mL into the microtube. The blood is allowed to stand for 15 minutes, then centrifuged at 3000 rpm for 20 minutes to get the serum, the serum is in the upper layer. Then the serum is used to determine SGPT activity.

2.8 SGPT examination

Pipette into microtube serum 100 μ L (0.1 mL) and one mL reagent I, mix well and let stand for 5 minutes. Then 0.25 mL of reagent II was added and homogeneously mixed. After 1 minute, absorption was measured with a UV-visible spectrophotometer at a wavelength of 365 nm every minute for 3 minutes, then the difference in mean absorption per minute was calculated. The formula can calculate the increase in SGPT:

$$\text{SPGT level (U/L)} = \Delta A/\text{minute} \times F$$

Where: $\Delta A/\text{minute}$ = Changes in average absorbances per minute

$$F = 3235$$

$$\Delta A/\text{minute} = [\text{Abs Test 2-Abs Test 1} + (\text{Abs Test 3-Abs Test 2})] / 2$$

2.9 Work on the liver histology of mice

1. The liver of the sacrificed experimental animal is taken (object), cleaned and put into a physiological NaCl solution for 30 minutes
2. The object is transferred to Bouin fixative solution
3. The object network is dehydrated with an alcohol solution of concentrations of 50, 70, 80, 90, and 96% and absolute alcohol for 1 hour.
4. Purification is done by moving objects into absolute alcoholic: xylol (1: 1) and xylol, for 1 hour each.



5. The object is inserted into the infiltration solution which is carried out in an incubator at a temperature of 56-60 °C.
6. Planting, the object is inserted into a metal mold which already contains liquid paraffin heated in an incubator, then left to cool and freeze.
7. Cutting, done by installing a paraffin block in the holder, then slicing it with a microtome knife as thin as possible (5 µm).
8. Attachment, glass object rubbed with Mayer's albumin. Placed some incisions on it, then dripped with water and stretched on a hot plate. After drying, then declined with xylol for 30 minutes.
9. Staining with hematoxylin-eosin dyes is carried out as follows: Alcohol: xylol (1: 1), alcohol 100, 96, 90, 80, 70, and 50% for 3 minutes each, hematoxylin-eosin for 1-5 minutes, then washed with water, when viewed under a microscope the cell nucleus was stained.
10. Advanced work with Alcohol 50, 70, 80, and 96% 3 minutes each, alcohol eosin for 15 minutes, 96% alcohol (1 minute), absolute alcohol (2 minutes), alcohol mixture: xylol (1: 1) for 2 minutes and xylol for a maximum of 30 minutes.
11. Closure, keep the tissue from drying out, dripping with an adhesive and then covered with a glass cover and dried
12. Preparations are labeled, then examined microscopically.

2.10 Microscopic observation of the liver

Histological observations of the liver include central veins, hepatocytes, hepatocyte cell structures, whereas abnormal liver abnormalities are observed in the form of degeneration/necrosis and inflammatory cells (inflammatory cells) in liver hepatocytes. Each preparation is assessed for its histological picture. Liver histological preparations are observed under a light microscope in five different fields of view, with a magnification of 400 times. Calculation of mean weight of liver histopathology change scores from five fields of view of each mouse was carried out. Assessment of liver damage based on scoring criteria "Histology Activity Index (HAI - Knodell Score)." The assessment uses two parameters (Knodell *et al.*, 1981):

Assessment criteria for liver histology

1. Scores for hepatocyte degeneration and necrosis

No.	The rate of change in liver damage	Score
1	Normal	1
2	Damage is less than 1/3 of the liver lobules	2
3	Damage in 1/3 - 2/3 lobules of the liver	3
4	Damage > 2/3 of liver lobules	4

2. Inflammatory cell score (inflammation)

No	The rate of change in liver damage	Score
1	Normal	1
2	Inflammatory cells <1/3 perivascular area	2
3	Inflammatory cells 1/3 - 2/3 perivascular area	3
4	Inflammatory cells > 2/3 perivascular area	4

2.11 Data analysis

One Way ANOVA test analyzed data from the effect of propolis on SGPT enzyme activity and liver histopathology. If the results of the analysis are significant ($P < 0.05$), then a follow-up test (post-hoc) is performed with the Duncan test.



3. Result and Discussion

3.1 SGPT Levels

A study of 24 white female mice was conducted. Provision of propolis can reduce SGPT levels in mice induced by valproic acid. The results of the calculation of the average SGPT levels of Group 1, Group 2, Group 3, and Group 4 were 9.976 ± 2.787 , 36.666 ± 9.130 , 23.993 ± 5.913 , and 28.332 ± 6.831 U/L, respectively (Table 1). There was a significant difference in the mean SGPT level between the control group and other treatment groups. However, there is no significant difference in mean levels between Group 3 and Group 4.

Table 1: Results of the measurement of SGPT levels

No. Mice	SGPT Levels (U/L)			
	Group 1	Group 2	Group 3	Group 4
1	9.71	40.44	22.65	38.82
2	11.33	37.20	33.97	32.35
3	6.47	51.76	21.03	24.36
4	8,09	29.12	25.88	21.03
5	14.56	35.59	16.18	22.65
6	9.71	25.88	24.26	30.73
Average \pm SD	$9,976 \pm 2,787$	$36,663 \pm 9,130$	$23,993 \pm 5,913$	$28,323 \pm 6,831$

Liver damage parameters used in this study are SGPT activity and liver histology. SGPT enzyme levels are used as parameters for liver damage because when liver damage occurs, hepatocyte cells will be permeable so that the SGPT enzyme will leak into the blood vessels and cause high levels in the serum (Huang *et al.*, 2006). Histology of the liver is a specific parameter because it immediately sees liver cells undergoing degeneration. The level of liver damage is comparable to SGPT levels in the blood (Ramadan *et al.*, 2015).

Based on the research that has been done, levels of SGPT of Group 1, Group 2, Group 3, and Group 4 showed 9.976 ± 2.787 , 36.666 ± 9.130 , 23.993 ± 5.913 , and 28.332 ± 6.831 U/L, respectively (Table 1). One-way ANOVA test then analyzed the SGPT level, and there was a significant difference between groups with a $P < 0.05$, followed by a post hoc Duncan new multiple range tests showed that there were significant differences between each treatment group. These results indicate that propolis significantly affected SGPT levels in mice ($P < 0.05$). SGPT levels of the group induced by valproic acid were higher than those in the control group, doses of 280 mg/kg and 560 mg/kg BW. However, the results showed that the level of SGPT in the 560 mg/kg BW propolis dose group was slightly higher than the dose group 280 mg/kg BW, but after statistically analyzed there was no significant difference in the mean SGPT level between the groups dose 280 mg/kg BW and 560 mg/kg BW.

The valproic acid produces 4-ene-VPA and 2,4-diene-VPA which act as free radicals so that the prooxidant properties are more dominant than their antioxidant properties. This condition is called oxidative stress. Oxidative stress induces disruption of calcium homeostasis which ultimately affects cellular metabolic processes. Oxidative stress causes lipid peroxidation which results in damage to cell membranes. Morphological and biochemical changes then followed by cell function disorders and ended hepatocyte death (Kuntz & Kuntz, 2006). Significantly higher levels of SGPT enzymes evidenced the occurrence of this oxidative reaction in the valproic acid induction group ($P < 0.05$) when compared with the control group, the dose group was 280 mg/kg and 560 mg/kg BW. Changes in serum SGPT enzyme levels in groups of mice given propolis are thought to be related to the content of compounds found in propolis, namely flavonoids that act as antioxidants. With the CAPE which is the active side of flavonoids contained in propolis can capture and reduce the activity of free radicals formed by the results of valproic acid metabolites. These antioxidants can give electrons to free radical molecules without being disturbed at all and can break the chain reaction of free radicals to prevent oxidative stress (Almatsier, 2002). Antioxidants are compounds that can neutralize a free radical.

3.2 Liver cell degeneration

Provision of propolis can reduce the score of degeneration and necrosis of liver cells induced by valproic acid. Degeneration scores and mean liver cell necrosis in Group 1, Group 2, Group 3, Group 4 were 1.000 ± 0.000 , 2.600 ± 0.438 , and 1.933 ± 0.163 , 2.100 ± 0.167 , respectively (Table 2). Average liver cell degeneration scores between groups had significant differences ($p < 0.05$). There was a significant difference in the mean scores of liver cell degeneration scores between the control group and other treatment groups. However, there was no significant difference in the mean liver cell degeneration score between Group 3 and Group 4.

Table 2: Calculation results of liver cell degeneration score

No. Mice	Liver cell degeneration score			
	Group 1	Group 2	Group 3	Group 4
1	1.00	2.20	2.00	2.40
2	1.00	3.00	2.00	2.20
3	1.00	3.00	2.00	2.00
4	1.00	3.00	2.00	2.00
5	1.00	2.20	2.00	2.00
6	1.00	2.20	1.60	2.00
Average \pm SD	1.000 ± 0.000	2.600 ± 0.438	1.933 ± 0.163	2.100 ± 0.167

Based on the research that has been done, it is found that degeneration and necrosis of liver cells in mice in Group 1 (control group); Group 2 (induction of valproic acid); and Groups 3 and 4 (groups given propolis at doses of 280 mg/kg and 560 mg/kg body weight) were 1.000 ± 0.000 , 2.600 ± 0.438 , 1.933 ± 0.163 , and 2.100 ± 0.167 , respectively (Table 2).

In one way ANOVA testing there were differences in mean cell degeneration and necrosis scores that were significant between groups ($p < 0.05$). To see these differences, continued with the Duncan new post hoc multiple range test. The result is a real difference between the control groups; valproic acid induction group; the group given propolis at a dose of 280 mg / kg body weight and 560 mg/kg body weight where the valproic acid induction group was the group with the highest liver histology score indicating that the liver in this group suffered the most damage. In the propolis group the dose of 560 mg/kg body weight had a slightly higher cell degeneration score than the propolis dose 280 mg/kg BW, but after analyzing this test, there was no significant difference between the two groups with $P < 0.05$

Valproic acid was given at a dose of 350 mg/kg body weight for 14 days, causing hepatocyte damage because valproic acid treatment produced 4-ene-VPA and (E)-2,4-diene-VPA metabolites which caused oxidative stress that produced hydrogen peroxide. According to Trisnowati (2009), hydrogen peroxide can react with compounds in the body and form highly reactive hydroxyl radicals. The hydroxyl radical causes lipid peroxidation. Lipid peroxidation causes damage to cell membranes and then causes the cell structure to become abnormal and damage cell function. Because the function of hepatocyte cells is damaged, hepatocytes lose cell integrity and cell polarity. Loss of cell polarity causes redistribution of membrane proteins, Na^+ , K^+ -ATPase and other proteins to hepatocyte cells resulting in accumulation of fat and water in hepatocytes which are characterized by degeneration in hepatocytes. Furthermore, cell death occurs apoptosis and necrosis (Trisnowati, 2009).

According to Lu (1995), hepatocytes are the type of cells that make up most of the liver organ. Hepatocytes are responsible for the central role of the liver in metabolism. These cells are located between sinusoids filled with blood and bile ducts. If the liver cell is damaged due to various factors, a series of morphological changes will occur in the liver cell. These changes can be sublethal, i.e., degenerative or lethal in the form of necrotic.

3.3 Liver cell inflammation

Provision of propolis can reduce the inflammatory cell (inflammation) score in the liver of the experimental animal. The average inflammatory cell score was Group 1, Group 2, Group 3, Group 4 were 1.000 ± 0.000 , 3.767 ± 0.294 , 2.000 ± 0.000 , and 3.133 ± 0.393 , respectively (Table 3). The average inflammatory cell score

between groups had a significant difference with ($p < 0.05$). There was a significant difference in the mean score of liver cell degeneration between the control group and other treatment groups.

In the results of the observation, changes in the histological structure of hepatocytes found that in all groups there were found cell changes in the form of degeneration, inflammatory cells (inflammatory cells) and necrosis. Degenerative change is a change in which the process is reversible, that is, can return to its original state, meaning that if the stimuli that cause cell damage are stopped, then the cell will return to health as before given stimulation. Conversely, necrosis is a change whose process is irreversible. Cells that experience necrosis can no longer return to normal. At the end point of necrosis, the cell will experience death. Theoretically, the process of liver cell damage begins with the regeneration process with the characteristics of cell swelling. These characteristics were observed in the valproic acid treatment. Valproic acid treatment appears to cause massive amounts of extracellular fluid to enter the cytosol.

Table 3: Results of calculation of inflammatory cell score (leukocytes) in the liver of mice

No. Mice	Inflammatory cell score (leukocytes) in the liver of mice			
	Group 1	Group 2	Group 3	Group 4
1	1.00	4.00	2.00	3.00
2	1.00	4.00	2.00	3.80
3	1.00	3.40	2.00	2.80
4	1.00	3.80	2.00	2.80
5	1.00	3.40	2.00	3.40
6	1.00	4.00	2.00	3.00
Average \pm SD	1.000 \pm 0.000	3,.67 \pm 0.294	2.000 \pm 0.000	3.133 \pm 0.393

The parameters used in this study are the liver histology, which aims to see little liver damage in further evidence. Although SGPT is sensitive to show liver cell damage, the examination of this enzyme is less specific, so histology is needed. The ingredients needed for the preparation of liver histology preparations are 10% formalin solution for storing the organ so that it is not damaged, alcohol (70%, 80%, 90% and absolute alcohol) for the dehydration process, liquid for infiltration process, hematoxylin-eosin for coloring.

According to Hariyatmi (2004), one of the changes induced by free radicals is the change like cell membranes and cytoplasmic membranes in cell elements such as mitochondria and lysosomes caused by fat peroxide. After damaging the cell membrane, toxic effects can also reach the nucleus and damage it, which results in abnormal cell structure and eventually leads to necrosis. Necrosis is irreversible degradation or cellular disorganization or body tissue cell death.

In the observations there were differences in microscopic images of the liver between the control groups; valproic acid induction group; a group given propolis at a dose of 280 mg/kg BW and 560 mg/kg BW. There were differences in morphology of hepatocytes, in the control group a few hepatocytes experienced degeneration (Figure 1). Hepatocytes in normal conditions are also replaced periodically, some also undergo a degeneration process by various causes, such as cell aging or accumulation of toxic materials, but degenerative cells are microscopic, usually less than 3%. In the valproic acid induction group, there are many hepatocytes with signs of degeneration or necrosis (Figure 2). In the treatment group with the application of propolis, hepatocytes appeared with fewer intracytoplasmic vacuoles than the valproic acid induction group. The vacuole reaction is lighter in the treatment with propolis at a dose of 280 mg/kg BW compared to a dose of 560 mg/kg BW (Figures 3 and 4).

In addition to signs of degeneration and necrosis, in microscopic observations of the liver also seen inflammatory cells (inflammation), obtained inflammatory cell scores in Group 1 mice (controls); Group 2 (induction of valproic acid); Groups 3 and 4 (the group gave propolis at a dose of 280 mg/kg BW and 560

mg/kg BW) were respectively 1.000 ± 0.000 , 3.767 ± 0.294 , 2.000 ± 0.000 , and 3.133 ± 0.393 (Table 3). One-way ANOVA test then analyzed the inflammatory cell score, and there was a significant difference between groups with a P value <0.05 so that Duncan's new multiple range tests continued it. The result is a significant difference between each treatment group.

In the control group, there were only a few perivascular or intrasinusoidal inflammatory cells, whereas in the valproic acid induction group there were many inflammatory cells which were mostly perivascular, small sinusoidal cells which contained inflammatory cells (leukocytes) (Figure 2). In the group treated with propolis, there was a decrease in inflammatory cells which showed an anti-inflammatory effect of propolis on the liver after drug administration. There is a slightly higher number of inflammatory cells in the propolis group at a dose of 560 mg/kg BW compared to a dose of 280 mg/kg BW. It allows the toxic effects of propolis or the effect of inflammatory induction at a dose of 560 mg/kg body weight. It also applies to a slightly higher picture of degeneration and necrosis in the 560 mg/kg BW dose group than the 280 mg/kg BW dose.

Similar to SGPT, histopathology testing decreased the mean score of liver cell degeneration and necrosis and decreased inflammation cell scores between treatment groups. The average score of degeneration and liver cell necrosis and inflammatory cells in the propolis group at a dose of 280 mg/kg and 560 mg/kg BW were lower than the average liver cell damage score in the valproic acid induction group. It means that propolis can minimize damage to liver cells so that propolis can give a hepatoprotective effect on white mice induced by valproic acid.

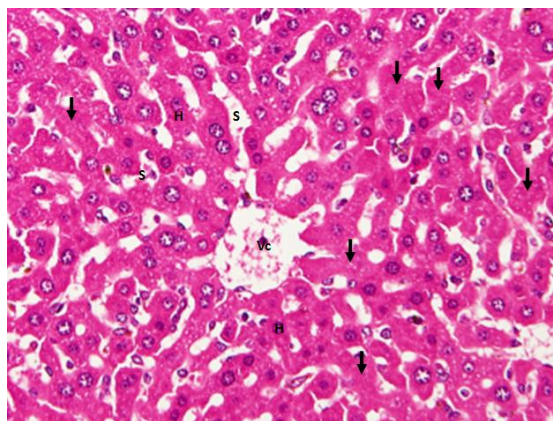


Figure 1: Histology of the liver tissue of control group mice with 400x magnification. Hepatocytes (H) are arranged in a plate of hepatocytes, with sinusoidal (S) between the hepatocyte plate, few hepatocytes show a reasonable number of degenerative signs (arrow). Sinusoid contains erythrocytes and little leukocytes. Central vein (Vc).

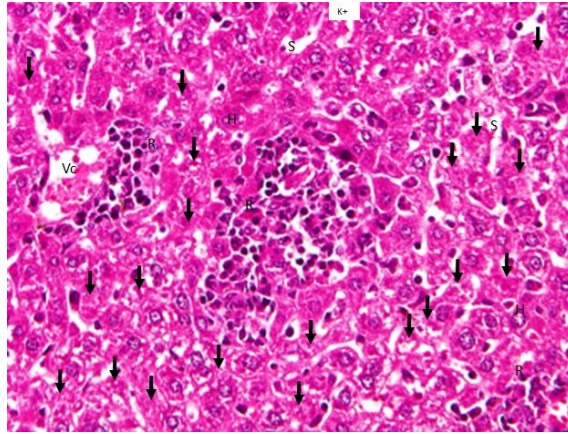


Figure 2: Histology of the liver tissue of valproic acid induction mice with 400x magnification. Most hepatocytes experience degeneration signs (arrows) with vacuole cytoplasm or blurry nuclei and lysis. Hepatocytes are arranged in plates with sinusoids between the hepatocyte plate, sinusoids that appear narrow containing inflammatory cells (leukocytes). Some leukocytes cluster around the vascular and in the liver parenchyma (R). Central vein (Vc).

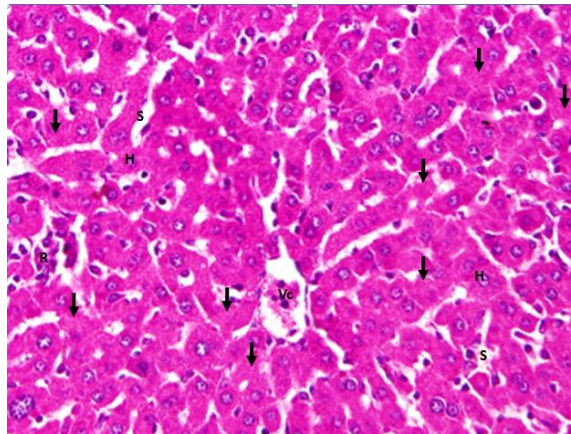


Figure 3: Histology of experimental liver tissue in propolis dose group 280 mg/kg BW + valproic acid with 400x magnification. Hepatocytes are arranged in plates with sinusoid between hepatocyte plate plates, sinusoids containing inflammatory cells (leukocytes), some leukocytes cluster around vessels and in the parenchyma, some hepatocyte cells show signs of degeneration (arrow), central vein (Vc), hepatic vein (Vh).

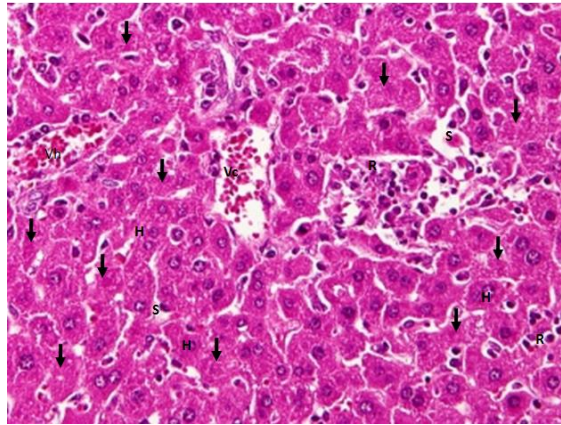


Figure 4: Histology of the liver tissue of experimental animals 580 mg/kg BW + valproic acid with 400x magnification. Hepatocytes appear in plates with sinusoid between hepatocyte plate, sinusoid containing inflammatory cells (leukocytes), some leukocytes cluster around vessels and in the parenchyma, some hepatocyte cells show signs of degeneration (arrow), central vein (Vc), hepatic vein (Vh)

4. Conclusion

Provision of propolis at a dose of 280 mg/kg BW and 560 mg/kg BW gave a hepatoprotective effect on white mice induced by valproic acid. Provision of propolis at 280 mg/kg BW and 560 mg/kg BW can reduce SGPT levels, liver cell degeneration scores and inflammatory (inflammation) cell scores in liver mice induced by valproic acid. Statistically, propolis dose of 280 mg/kg BW is equal to propolis 560 mg/kg BW, but microscopically there are differences in histological features. Propolis at a dose of 560 mg/kg BW shows signs of degeneration and the number of inflammatory cells is slightly higher than the propolis dose of 280 mg/kg BW. So propolis dose of 280 mg/kg BW is the best and effective dose used as a hepatoprotective agent.

References

1. Almatsier, S. (2002). *Prinsip dasar ilmu gizi*. Jakarta: Gramedia Pustaka Utama.
2. Bankova, V. (2005). Recent trends and important developments in propolis research. *Evidence-based complementary and alternative medicine*, 2(1), 29-32.
3. Bendich, A. (1993). Physiological role of antioxidants in the immune system. *Journal of Dairy Science*, 76(9), 2789-2794.
4. Bhadauria, M., Nirala, S. K., & Shukla, S. (2007). Duration-dependent hepatoprotective effects of propolis extract against carbon tetrachloride-induced acute liver damage in rats. *Advances in therapy*, 24(5), 1136-1145.
5. Búfalo, M. C., & Sforcin, J. M. (2015). The modulatory effects of caffeic acid on human monocytes and its involvement in propolis action. *Journal of Pharmacy and Pharmacology*, 67(5), 740-745.
6. Cadenas, E., & Packer, L. (2002). Expanded Caffeic Acid and Related Antioxidant Compound: Biochemical and Cellular Effects. *Handbook of Antioxidants*, 279-303.
7. Cinthya, E., Ivan, S., & Pradipta, R. A. (2012). Use of Liver Damage-Inducing Drugs in Hospitalized Patients with Liver Disease. Department of Pharmacology and Clinical Pharmacy, Faculty of Pharmacy, Padjadjaran University.
8. Crawford, J.M. (2007). *Hati dan Saluran Empedu*. In: Robbins S. L., Vinay K., Ramzy S. C.. Robbins Buku Ajar Patologi. Volume 2. Edisi 7. Alih Bahasa: Pendi B. U. Jakarta: Penerbit Buku Kedokteran EGC.
9. Dota, K. F. D., Consolaro, M. E. L., Svidzinski, T. I. E., & Bruschi, M. L. (2011). Antifungal activity of Brazilian propolis microparticles against yeasts isolated from vulvovaginal candidiasis. *Evidence-Based Complementary and Alternative Medicine*, Volume 2011, Article ID 201953, 8 pages doi:10.1093/ecam/neq029



Harrizul Rivai *et al*, Int. Journal of Pharmaceutical Sciences and Medicine (IJPSM),
Vol.3 Issue. 8, August- 2018, pg. 1-12

ISSN: 2519-9889

Impact Factor: 3.426

10. Fabris, S., Bertelle, M., Astafyeva, O., Gregoris, E., Zangrando, R., Gambaro, A., Lima, G. P. P. & Stevanato, R. (2013). Antioxidant properties and chemical composition relationship of Europeans and Brazilians propolis. *Pharmacology & Pharmacy*, 4(01), 46-51.
11. Funakoshi-Tago, M., Okamoto, K., Izumi, R., Tago, K., Yanagisawa, K., Narukawa, Y., Kiuchi, F., Kashahara, T. & Tamura, H. (2015). Anti-inflammatory activity of flavonoids in Nepalese propolis is attributed to inhibition of the IL-33 signaling pathway. *International Immunopharmacology*, 25(1), 189-198.
12. Ganong, W. F. (2008). *Buku Ajar Fisiologi Kedokteran*, ed. 22, terjemahan Brahm UP, Jakarta: Penerbit Buku Kedokteran EGC
13. Hariyatmi. (2004). Kemampuan Vitamin E Sebagai Antioksidan Terhadap Radikal Bebas Pada Lanjut Usia. *Jurnal MIPA*, 14(1): 52 – 60.
14. Huang, X. J., Choi, Y. K., Im, H. S., Yarimaga, O., Yoon, E., & Kim, H. S. (2006). Aspartate aminotransferase (AST/GOT) and alanine aminotransferase (ALT/GPT) detection techniques. *Sensors*, 6(7), 756-782.
15. Indonesian Heart Research Association (2013), Drug-induced Hepatitis/Drug-Induced Liver Injury (DILI). Jakarta: PPHI
16. Isabel Lucena, M., García- Cortés, M., Cueto, R., Lopez- Duran, J. L., & Andrade, R. J. (2008). Assessment of drug- induced liver injury in clinical practice. *Fundamental & clinical pharmacology*, 22(2), 141-158.
17. Knodell, R. G., Ishak, K. G., Black, W. C., Chen, T. S., Craig, R., Kaplowitz, N., Kiernan, T. W. & Wollman, J. (1981). Formulation and application of a numerical scoring system for assessing histological activity in asymptomatic chronic active hepatitis. *Hepatology*, 1(5), 431-435.
18. Kolankaya, D., Selmanoğlu, G., Sorkun, K., & Salih, B. (2002). Protective effects of Turkish propolis on alcohol-induced serum lipid changes and liver injury in male rats. *Food Chemistry*, 78(2), 213-217.
19. Krisnansari, D., Sulistyono, H., & Ati, V. R. B. (2014). Efek Propolis Terhadap Fungsi Dan Perlemakan Hati Tikus Putih (*Rattus Norvegicus*) Model Hiperkolesterolemia. *Penelitian Gizi dan Makanan (The Journal of Nutrition and Food Research)*, 37(1), 77-85.
20. Kuntz, E., & Kuntz, H. D. (2006). *Hepatology, Principles and practice: history, morphology, biochemistry, diagnostics, clinic, therapy*. Springer Science & Business Media.
21. Lu, F. C. (1995). Toksikologi Dasar: Asas, Organ sasaran dan Penilaian resiko. Penerjemah: Edi Nugroho, Zunilda SB dan Iwan Darmansyah. Jakarta: UI Press
22. Mehta, N. (2016), Drug-Induced Hepatotoxicity. <http://emedicine.medscape.com/article/169814-overview>. (accessed 12 August 2018)
23. Ministry of Health, (2007), *Pharmaceutical Care for Liver Disease*, Jakarta: Indonesian Ministry of Health
24. Nakajima, Y., Shimazawa, M., Mishima, S., & Hara, H. (2009). Neuroprotective effects of Brazilian green propolis and its main constituents against oxygen- glucose deprivation Stress, with a gene- expression analysis. *Phytotherapy Research: An International Journal Devoted to Pharmacological and Toxicological Evaluation of Natural Product Derivatives*, 23(10), 1431-1438.
25. Perucca, E. (2002). Pharmacological and therapeutic properties of valproate. *CNS Drugs*, 16(10), 695-714.
26. Ramadan, A., Soliman, G., Mahmoud, S. S., Nofal, S. M., & Abdel-Rahman, R. F. (2015). Hepatoprotective and hepatotherapeutic effects of propolis against D-galactosamine/lipopolysaccharide-induced liver damage in rats. *Int. J. Pharm. Pharm. Sci*, 7(2), 372-378.
27. Sacher, R. A., McPherson, R. A., & Campos, J. M. (1991). *Widmann's clinical interpretation of laboratory tests* (pp. 416-443). Philadelphia: FA Davis.
28. Sawicka, D., Car, H., Borawska, M. H., & Nikliński, J. (2012). The anticancer activity of propolis. *Folia histochemica et cytobiologica*, 50(1), 25-37.
29. Seidel, V., Peyfoon, E., Watson, D. G., & Fearnley, J. (2008). Comparative study of the antibacterial activity of propolis from different geographical and climatic zones. *Phytotherapy Research*, 22(9), 1256-1263.
30. Sonderup, M. W. (2006). Drug-Induced Liver Injury is a Significant Cause of Liver Disease. *Including Chronic Liver, Drug-Induced Liver Injuries*, 29(6).
31. Tajiri, K., & Shimizu, Y. (2008). Practical guidelines for diagnosis and early management of drug-induced liver injury. *World journal of gastroenterology*, 14(44), 6774-6785.
32. Trisnowati, D. (2009). Efek Pemberian Jus Buah Jambu Biji Merah (*Psidium guajava* Linn) terhadap Kerusakan Sel Hati yang Dipapari dengan Minyak Goreng Bekas. *Skripsi*. Surakarta: Fakultas Kedokteran, Universitas Negeri Surakarta.
33. Veronica, S. (2016). Efek “bee glue” sebagai hepatoprotektor Kerusakan hati mencit yang diinduksi Karbon tetraklorida (CCl₄). *Skripsi*, Padang: Fakultas Farmasi Universitas Andalas
34. Viuda- Martos, M., Ruiz- Navajas, Y., Fernández- López, J., & Pérez- Álvarez, J. A. (2008). Functional properties of honey, propolis, and royal jelly. *Journal of food science*, 73(9), R117-R124.



Harrizul Rivai *et al*, Int. Journal of Pharmaceutical Sciences and Medicine (IJPSM),
Vol.3 Issue. 8, August- 2018, pg. 1-12

ISSN: 2519-9889

Impact Factor: 3.426

35. Wai, C. T. (2006). Presentation of drug-induced liver injury in Singapore. *Singapore medical journal*, 47(2), 116.
36. Wulan, A. D. (2011). Efek Hepatoprotektor Propolis Terhadap Kerusakan Sel Hepar Mencit (*Mus musculus*) yang diinduksi Parasetamol. *Skripsi*. Surakarta: Universitas Sebelas Maret