



Majid Hadi Jassim *et al*, Int. Journal of Pharmaceutical Sciences and Medicine (IJPSM),  
Vol.4 Issue. 2, February- 2019, pg. 1-13

ISSN: 2519-9889

Impact Factor: 3.426

# Radiographic Anatomical Study of Intracranial Calcifications in Patients underwent Computerized Tomography Imaging

Majid Hadi Jassim<sup>\*</sup>; Nameer Tawfiq George<sup>\*\*</sup>; Mohammed Mohammed Jawad<sup>\*\*\*</sup>

<sup>\*</sup>Lecturer, Department of Anatomy and biology, college of medicine, Qadisyia University

<sup>\*\*</sup>Assistant Professor, Department Of Human Anatomy, College of Medicine, Baghdad University

<sup>\*\*\*</sup>Specialist, Department Of Radio- diagnostic and imaging, Al – Kadhimia Teaching Hospital

## Abstract

### Background:

Intracranial calcification is a condition in which calcium deposit on the wall of blood vessels at various sites of the brain tissues. The calcification can be normal or pathological.

### Method:

The study involved 440 Iraqi patients, 238 were male, 126 have calcifications and 202 were female, 124 have calcification, who underwent cranial computed tomography imaging.

### Aim of the study:

To identify the relation between intracranial calcification and age of patient.

### Result:

A significant association was found between gender and frequency of calcifications ( $P = 0.03$ ). A significant association was found between age and frequency of calcifications ( $P < 0.001$ ). A significant difference ( $P = 0.02$ ) among males and females in relation to the anatomical sites of their intracranial calcifications.

Although the calcification process could be physiological and increases with age, but it is a process of reactive-adaptative variability, given by the complex of variables; sex – constitutional ground – neuro-endocrine context.



**Conclusion:**

The calcifications were incidental findings on CT imaging of the brain. There were no relation between the site of calcifications and the patient complaint thus it can be concluded that the intracranial calcification could be considered as a normal consequence of vessel degeneration and aging, and that the phenomenon of calcification in glands and other organs could be associated with dysfunctions.

**Key word:** Calcification is a normal consequence of vessel degeneration.

**Introduction**

**1-1 Normal intracranial calcifications:**

Intracranial calcification is a condition in which calcium deposits on the wall of blood vessels at various sites of the brain tissues. Normal calcifications occur in special locations and are usually asymptomatic, while abnormal calcifications might be symptomatic depending on the site and extent of calcification<sup>1</sup>.

The phenomenon of calcification in gland and other organ is associated with dysfunctions. So the calcification can be normal or pathological<sup>2</sup>.

The normal intracranial calcification can occur in various sites as in table1-1<sup>3</sup>.

**Table 1-1:** Normal intracranial calcification by CT<sup>3</sup>.

Site	Percentage
Pineal body	60%
Habenular nuclei	30%
Petroclinoid and interclinoid	12%
Dura mater (falx cerebri)	7%
Choroid plexus	10%
Pituitary gland	Rare
Carotid arteries	Common in elderly



## **1-2 Pathologic intracranial calcifications:**

Pathological intracranial calcification may be classified as in table 1-2<sup>4</sup>.

**Table 1-2:** Pathological intracranial calcification<sup>4</sup>.

### **1. Neoplasms:**

Craniopharyngioma, Glioma, Meningioma, Ependymoma, Papilloma of the choroids plexus, Pinealoma, Chordoma, Dermoid, epidermoid, and teratoma, Hamartoma, Lipoma, Pituitary adenoma (rarely), Metastasis (rarely).

### **2. Vascular:**

Atheroma, Aneurysm, Angioma, Subdural hematoma, intracranial hematoma.

### **3. Infections and infestations:**

Toxoplasmosis, Cytomegalic inclusion body disease, Herpes, Rubella, Tuberculosis, Pyogenic abscess, Cysticercosis, Hydatid cyst, Trichinosis, Torulosis, Coccidioides.

### **4. Metabolic and miscellaneous:**

Idiopathic basal ganglia calcification, Hypoparathyroidism, Pseudohypoparathyroidism, Tuberous sclerosis, Sturge-Weber syndrome, Neurofibromatosis, Lissencephaly, Fahr's syndrome, Cockayne syndrome, X-radiation and methotrexate, Hemodialysis, Lead poisoning, CO poisoning.

## **Patients and Methods**

### **2-1 Patients:**

The study involved 440 Iraqi patients, 238 (54.1%) were male and 202 (45.9%) were female with age range between 1 and 86 years.

### **2-2 Materials:**

The computed tomography equipment used in this study was **Helical or Spiral 3D CT**.

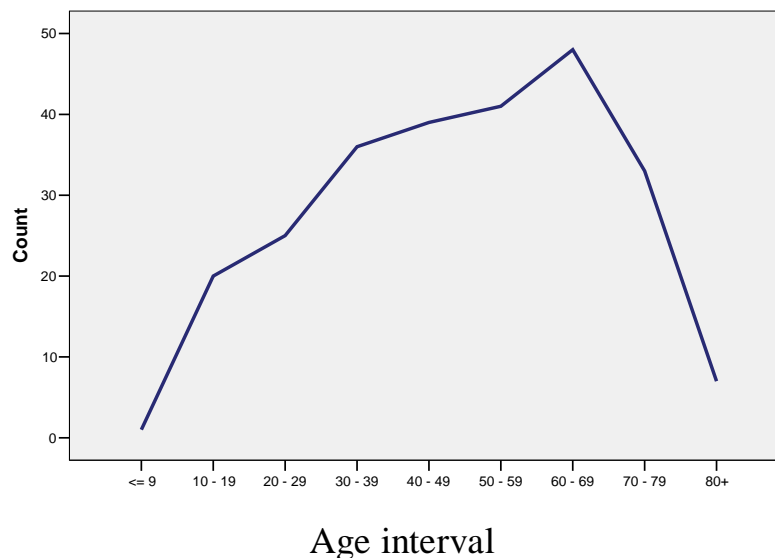
The helical or spiral CT machines have a computer systems integrate the data of the moving individual slices to generate three dimensional volumetric information (3D-CT scan). The data stream representing the varying radiographic

intensity sensed reaching the detectors then computer processed to calculate cross-sectional estimations of the radiographic density, expressed in Hounsfield units.

## Results

### **3-1 Age distribution of calcifications:**

We found calcification in 250 (56.8%) of the cases. The frequency of calcifications related to age groups is shown in figure 3-1. A significant association was found between age and frequency of calcifications ( $P < 0.001$ ).

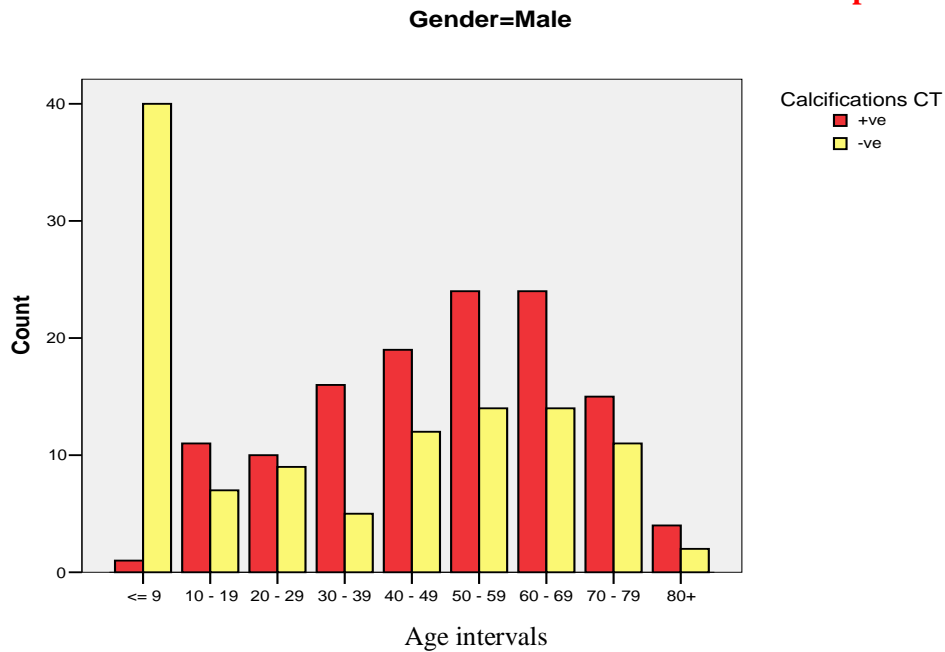


**Figure 3-1:** Frequency of calcifications related to age groups

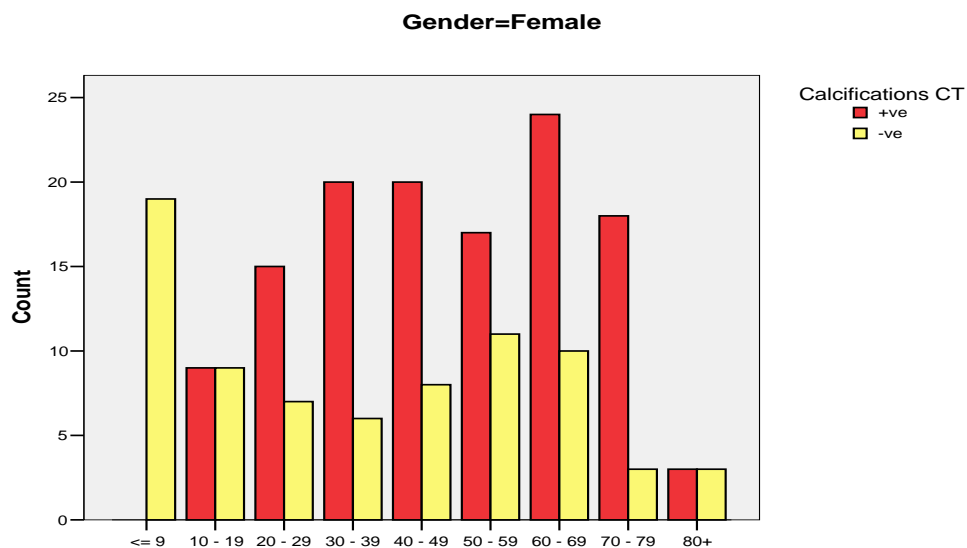
### **3-2 Gender distribution of calcifications:**

Of 238 males 124 (52.1%) have calcifications, and of 202 females 126 (62.3%) have calcification are shown in figure 3-2 and 3-3.

A significant association was found between gender and frequency of calcifications ( $P = 0.03$ ).



**Figure 3-2:** Distribution of calcification on age groups in male.

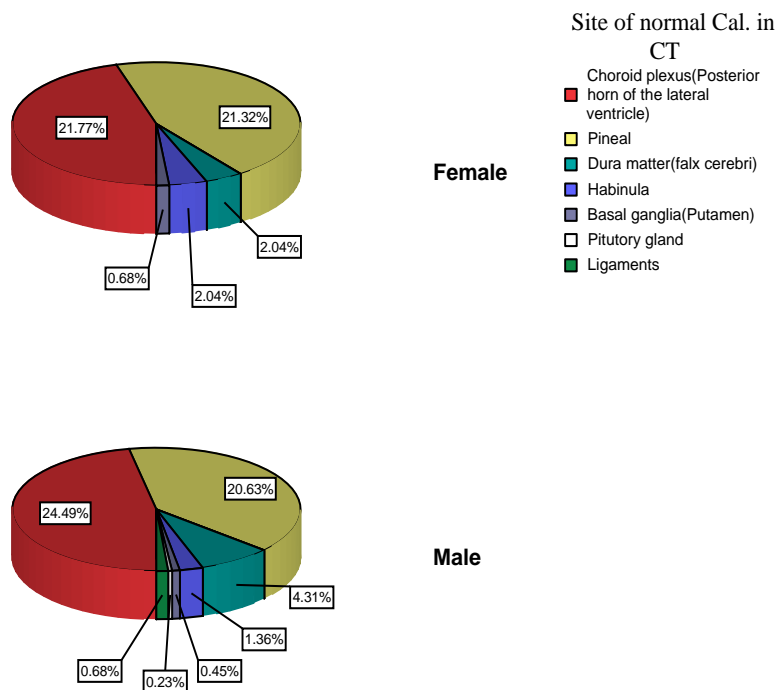


**Figure 3-3:** Distribution of calcification on age groups in female.

### 3-3 Site distribution of calcifications:

We found the calcifications in the following sites; in the falx cerebri of dura mater in 29 (11.2%) of cases, pineal body in 184 (73%) of cases, habenular commissure in 16 (6.4%) of cases, the choroid plexus of the posterior horn (trigone) of the lateral ventricle in 204 (81.6%) of cases, basal ganglia (putamen) in 36 (14.4%) of cases, pituitary gland in 1 (10.4%) of cases as seen by CT.

The site distribution of calcifications among males and females. The tests yielded significant results ( $P = 0.02$ ), suggesting difference relative to gender, figure 3-4.



**Figure 3-4:** Percentage of sites of calcifications on each gender.



## **Discussion**

### **4-1 Relation of calcifications with age and gender:**

We found that the overall intracranial calcification is present in 250 (56.8%) of the cases, of which 124 (52.1%) were males, and 126 (62.4%) were females. A significant association was found between gender and frequency of intracranial calcifications ( $P = 0.03$ ). A significant association was found between age and frequency of intracranial calcifications ( $P < 0.001$ ). The highly significant association of the intracranial calcification with age supports the impression that the intracranial calcification could be atherosclerotic in origin<sup>5</sup>.

Normal intracranial calcifications occur in special locations such as; pineal body, habenular commissure, choroid plexus, dura mater (falx cerebri), petroclinoid and interclinoid ligaments, pituitary gland, and carotid arteries which are usually asymptomatic, while abnormal intracranial calcifications might be symptomatic depending on the site and extent of calcification<sup>1</sup>. The phenomenon of calcification in glands and other organs was found to be associated with dysfunctions<sup>2</sup>.

### **4-2 Relations of the site of intracranial calcifications to the age and gender:**

#### **4-2-1 The pineal body calcification:**

In this study pineal calcification was found in 67.2% (168) of cases over the age of 20, and in 6.4% (16) of cases under the age of 20, pineal calcification range from 16.5% (15) to 22% (20) of cases with age from 40 to 69 years in males and



Majid Hadi Jassim *et al*, Int. Journal of Pharmaceutical Sciences and Medicine (IJPSM),  
Vol.4 Issue. 2, February- 2019, pg. 1-13

ISSN: 2519-9889

Impact Factor: 3.426

range from 17.2% (16) to 21.5% (20) of cases with age from 40 to 69 years in females, and there is highly significant correlation between pineal calcification and age groups in each gender ( $P < 0.001$  in male, and  $P = 0.004$  in female).

Previous studies showed that 55% of the adults the pineal calcified over the age of 20, and only in 20% that pineal calcification was under the age of 20<sup>6</sup>.

There is some degree of pineal calcification can be considered a normal consequence of vessel degeneration and aging<sup>7</sup>.

#### **4-2-2 Calcification in the choroid plexus:**

In our study, unilateral choroid plexus calcification of the posterior horn of the lateral ventricle was found in 1 (0.4%) of the cases in the age under 9 years, in 11 (4.4%) of cases aged from 10-19, in 27 (10.8%) of cases aged from 30-39, and in 6 (2.4%) of cases aged over 80 years.

Other studies showed that no choroid calcification was found under the age of 9 years, in 5.9% aged from 10 to 14 years, and in 17.4% aged from 15 to 19 years. The calcification was strikingly increased with increasing age. It was 51.5% of cases between 30 and 39 years of age, calcification was found in 74.4% of cases aged over 80 years<sup>8</sup>.

The site at which choroid plexus papillomas occurred in order of frequency, guided by images, were lateral ventricle (43%), fourth ventricle (39%), third ventricle (10%), and cerebellopontine angle (9%)<sup>9</sup>. The unilateral calcifications of the choroid plexus papillomas in 4% to 25% of children with choroid plexus papillomas have hydrocephalus<sup>10</sup>.





Majid Hadi Jassim *et al*, Int. Journal of Pharmaceutical Sciences and Medicine (IJPSM),  
Vol.4 Issue. 2, February- 2019, pg. 1-13

**ISSN: 2519-9889**

**Impact Factor: 3.426**

#### **4-2-3 The calcification in the habenula:**

In this study the habenular calcification was found in 16 (3.6%) of all the cases studied above the age of 9 years (The habenular calcification was found in 7 (2.9%) of cases were males, and in 9 (4.4%) of cases were females).

Other study showed that the frequency of habenular calcification is 15% of cases. The frequency of habenular calcification on CT of the chronic schizophrenic-patients was present in 87% of patients. The implications of habenular calcification for the pathophysiology of schizophrenia are attributed to the central role of the habenula in the regulation of limbic functions<sup>11</sup>.

#### **4-2-4 The dural (falx cerebri) calcification:**

The dural (falx cerebri) calcification constituted about 6.5% (29) of the cases in this study, with 8.5% (20) in males, and 4.5% (9) in female. Results in the dura matter calcification suggesting no difference relative to gender. Other studies showed that dural (falx cerebri) calcification constituted 0.8% of cases<sup>12</sup>.

The exact mechanism of the calcification of dura is unknown but is proposed to be arterial phenomenon or persistent venous congestion, with calcification occurring in chronic hyperperfused brain parenchyma or secondary to dystrophic changes in the walls of congested veins<sup>13</sup>.

In this study no cases of falx calcification was below the age of 9 years, and the falx calcification was in higher age group (60-69 years). Other studies showed that the intracranial falx calcification in children can be classified as physiologic or pathologic. Physiologic falx calcification is very uncommon (2%) below the age of 9 years and increases several fold as children approach 15 years of age. The



Majid Hadi Jassim *et al*, Int. Journal of Pharmaceutical Sciences and Medicine (IJPSM),  
Vol.4 Issue. 2, February- 2019, pg. 1-13

ISSN: 2519-9889

Impact Factor: 3.426

reported causes of pathologic falx calcification in children are from children with lissencephaly and pseudopseudohypoparathyroidism<sup>14</sup>.

#### **4-2-5 The calcifications of interclinoid and petroclinoid ligaments:**

In this study the interclinoid and petroclinoid ligaments calcifications were identified in only 2 (0.45%) of all cases studied.

Other study showed the calcifications of interclinoid ligament (bridged sella) were reported in 13% of cases<sup>15</sup>. The interclinoid ligament calcification may be associated with epilepsy and diabetes insipidus as a coincidental findings. While calcification of the petroclinoid ligament is typically considered to be an anatomic anomaly, it has been reported as a radiographic feature of basal cell carcinoma syndrome and systemic fluorosis<sup>16</sup>.

#### **4-2-6 The basal ganglia calcification:**

In this study the basal ganglia calcification was present in 36 (8.18%) of cases. The bilateral basal ganglia calcifications are sometimes familial, usually autosomal dominant, but also autosomal recessive<sup>17</sup>.

Basal ganglia calcification has been shown to be associated with endocrine conditions particularly hypoparathyroidism and pseudohypoparathyroidism, toxic or iatrogenic and mitochondrial disorder. There is marked cognitive impairment in patient with extensive basal ganglia calcification<sup>18</sup>. In the idiopathic basal ganglia calcification there is extensive bilateral calcifications in the pallidum and the putamen. The idiopathic or physiological basal ganglia calcification also termed pseudocalcification<sup>19</sup>.



Majid Hadi Jassim *et al*, Int. Journal of Pharmaceutical Sciences and Medicine (IJPSM),  
Vol.4 Issue. 2, February- 2019, pg. 1-13

ISSN: 2519-9889

Impact Factor: 3.426

#### **4-2-7 The pituitary calcification:**

In this study the pituitary calcification was found on one (0.22%) of cases. Other studies have shown that the pituitary calcification in normal subject is very rarely identified radiologically<sup>20</sup>.

#### **4-2-8 The intracranial internal carotid artery calcification:**

Incidental internal carotid artery calcifications identified on conventional skull radiographs and CT imaging have received much attention because of their potential predictive value for atherosclerosis disease, hypercholesterolemia, diabetes, cardiac disease, carotid arterial stenosis and stroke<sup>21,22</sup>. There is some degree of calcification that can be considered a normal consequence of vessel degeneration and aging<sup>23</sup>. The absence of correlation with significant risk factors for atherosclerotic disease also suggests that the internal carotid artery calcifications lie within the range of normal physiological calcification<sup>24</sup>.

It is suggested that the CT can be used as noninvasive way for studying intracranial atherosclerosis in subjects with normal intracranial calcifications.

## **References**

1. Izadi S. Intracranial calcification. Shiraz E-Medical Journal. 2003; 4(2): 29-39.
2. Danaila L, Golu M. Pineal neurophysiology. Bucuresti: Editura Med. 2000; 1: 526-541.
3. Newton T, Potts G. Radiology of the skull and brain: The Skull, vol 1. St. Louis: Mosby, 1971; pp. 343-350.
4. Sutton D, Stevens J, Miszkiel K. A textbook of radiology and imaging. 7<sup>th</sup> edition. London: Churchill Livingstone, 2003; pp. 1629.



Majid Hadi Jassim *et al*, Int. Journal of Pharmaceutical Sciences and Medicine (IJPSM),  
Vol.4 Issue. 2, February- 2019, pg. 1-13

**ISSN: 2519-9889**

**Impact Factor: 3.426**

5. Katada K, Kanno T, Sano H. Calcification of vertebral artery. *AJNR*. 1983; 4: 450-453.
6. Pawl R. P, Walter A. K. Localization of the calcified pineal body on lateral roentgenogram. *Am J of Roentgenology*. 1969; 105(2): 287-290.
7. Bergevin M. A, Daugherty C. C, Bove K. E. The internal carotid artery siphon in children and adolescent. *Hum Pathol*. 1991; 22: 603-606.
8. Kwak R, Takeuchi F, Yamamoto N, Nakamura T, Kadoya S. Intracranial physiological calcification on computed tomography: Calcification in the choroid plexus of the lateral ventricles. *No To Shinkei*. 1988; 40(8): 707-711.
9. Rovit. Choroid Plexus Papillomas. Observation on radiographic diagnosis. *AJR*. 1996; 110: 608-617.
10. Thompson J. R, Harwood-Nash D. C, Fitz C. R. The neuroradiology of children choroid plexus neoplasms. *AJR*. 1973; 118: 116-133.
11. Sandyk R. Pineal and habenula calcification in schizophrenia. *Int J Neurosci*. 1992; 67(1): 19-30.
12. Norman D, Diamond C, Boyd D. Relative detectability of intracranial calcification on computed tomography and skull radiography. *J Comput Assist Tomogr*. 1978; 2: 61-64.
13. Lai P. H, Chang M. H, Liang H. L. Unusual sign for dural arteriovenous fistula with diffuse basal ganglia and cerebral calcification. *Zhonghua Yi Xue Za Zhi (Taipei)*. 2009; 63: 329-333.
14. Kendall B, Cavanagh N. Intracranial calcification in paediatric computed tomography. *Neuroradiology*. 1986; 28: 324-330.
15. Jewett C. H. Teleroentgenography of the sella turcica with observations on one hundred normal cases. *Am J Roentgenol*. 1920; 7: 352-355.
16. Berg D. Nevoid basal cell carcinoma syndrome. *E Medicine J*. 2001; 2: 1-10.
17. Bollier F, Bollier M, Gilbert J. Familial idiopathic cerebral calcifications. *J Neurol Neurosurg Psychiatr*. 1977; 40: 280-285.
18. Levy G. Basal ganglia calcification (striopallidodentate calcification) and cognitive impairment. *Arq Neuropsiquiatr*. 1999; 57(1): 147-150.
19. Ostertag B. Die an bestimmte Lokalisation gebundenen Konkremete des Zentralnervensystems und ihre Beziehung zur"Verkalkung intercerebraler GefaBe" bei gewissen endokrinen Erkrankungen. *Virchows Arch. Path. Anat*. 1929; 275: 828-239.



Majid Hadi Jassim *et al*, Int. Journal of Pharmaceutical Sciences and Medicine (IJPSM),  
Vol.4 Issue. 2, February- 2019, pg. 1-13

**ISSN: 2519-9889**

**Impact Factor: 3.426**

20. Savy L. E, Moseley I. F. Intracranial arterial calcification and ectasia in visual failure. *Br J Radiol.* 1996; 69: 394-401.
21. Cohen S. N, Friedlander A. H, Jolly D. A. Carotid calcification on panoramic radiographs: an important marker for vascular risk. *Oral Surg Oral Med Oral Pathol Oral Radiol Endod.* 2002; 94: 510-514.
22. Ptak T, Hunter G. H, Avakian R. Clinical significance of cavernous carotid calcification encountered on head computed tomography scan performed on patient seen in the emergency department. *J comput Assist Tomogr.* 2003; 27: 505-509.
23. Bergevin M. A, Daugherty C. C, Bove K. E. The internal carotid artery siphon in children and adolescent. *Hum Pathol.* 1991; 22: 603-606.
24. Koch B, Blackham A, Jones B. Incidental internal carotid artery calcifications on temporal bone CT in children. *Pediatr Radiol.* 2009; 37: 141-144.